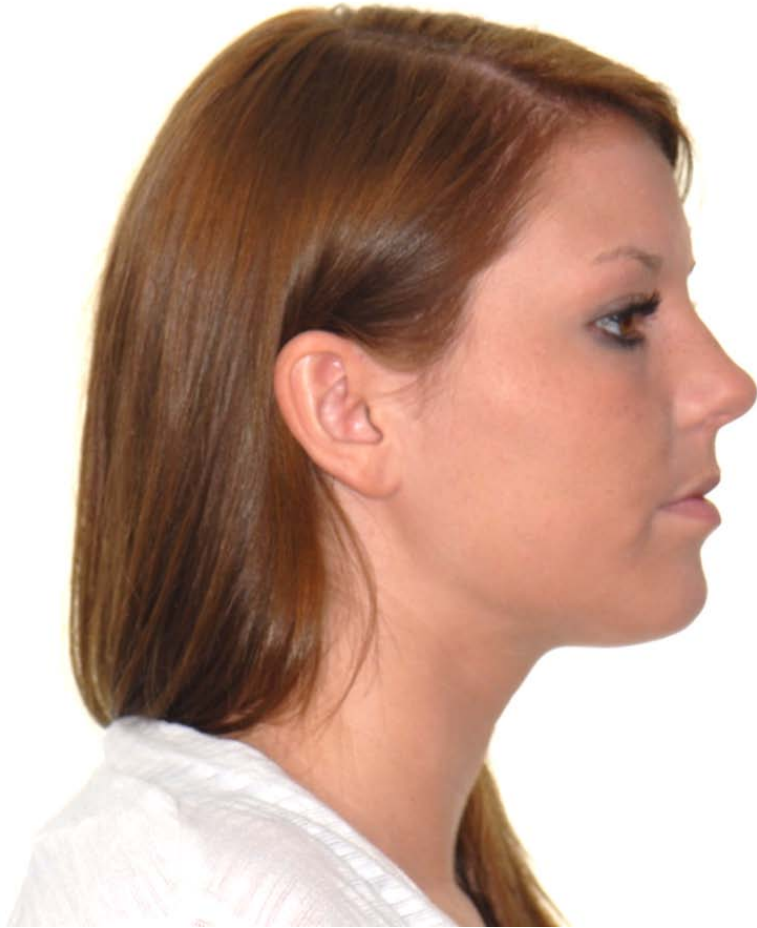

Ideal Photographs And Radiographs



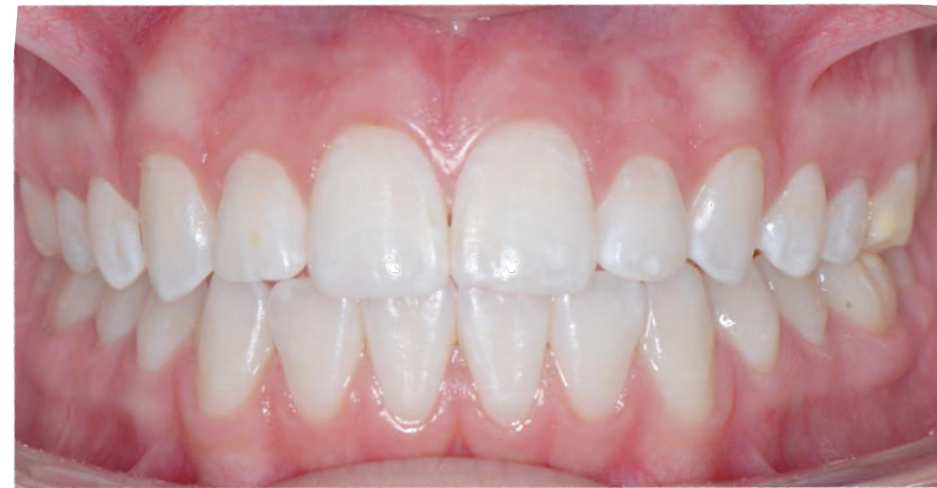- Teeth in occlusion
- Lips relaxed and in contact
- Natural head position with eyes looking forward
- Entire head and neck displayed
- Left eyelash slightly visible
- Approximate center of frame is 1.0 cm anterior to tragus
- White, or light, background



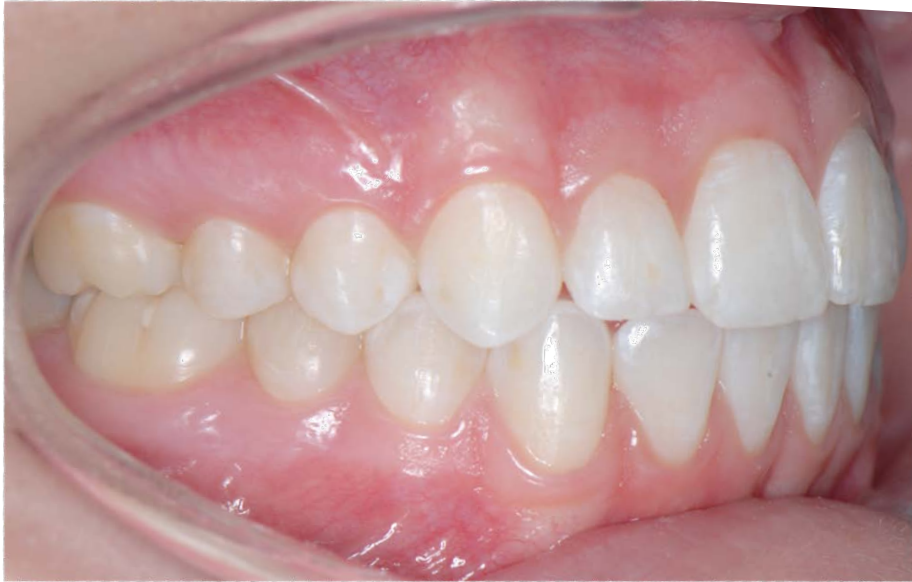- Patient simply turns to face the camera
- Eyes are open and looking into camera
- Ears exposed
- No distracting eyewear or jewelry
- Inter-pupillary line horizontal to the frame
- Approximate center of frame is the tip of the nose



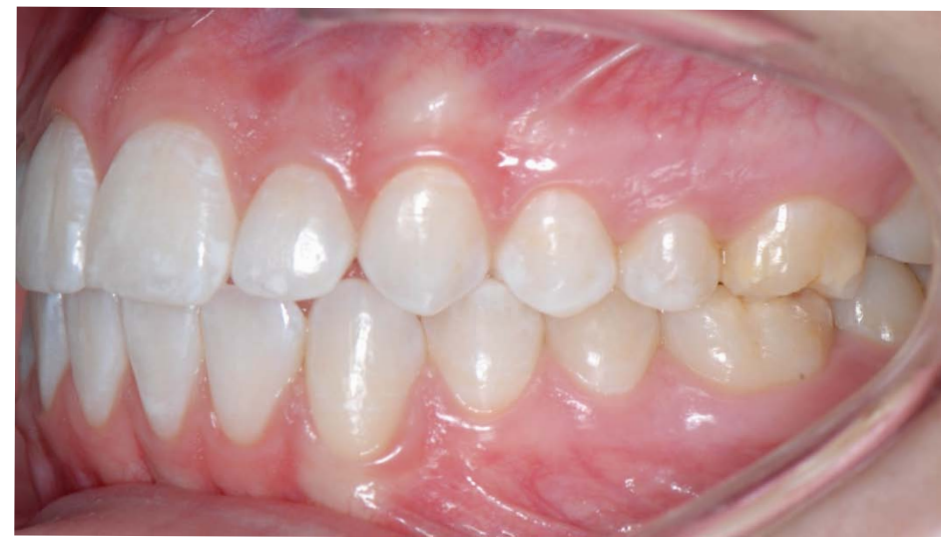- Use the same format as the non-smiling frontal photograph adding a natural smile (social smile)



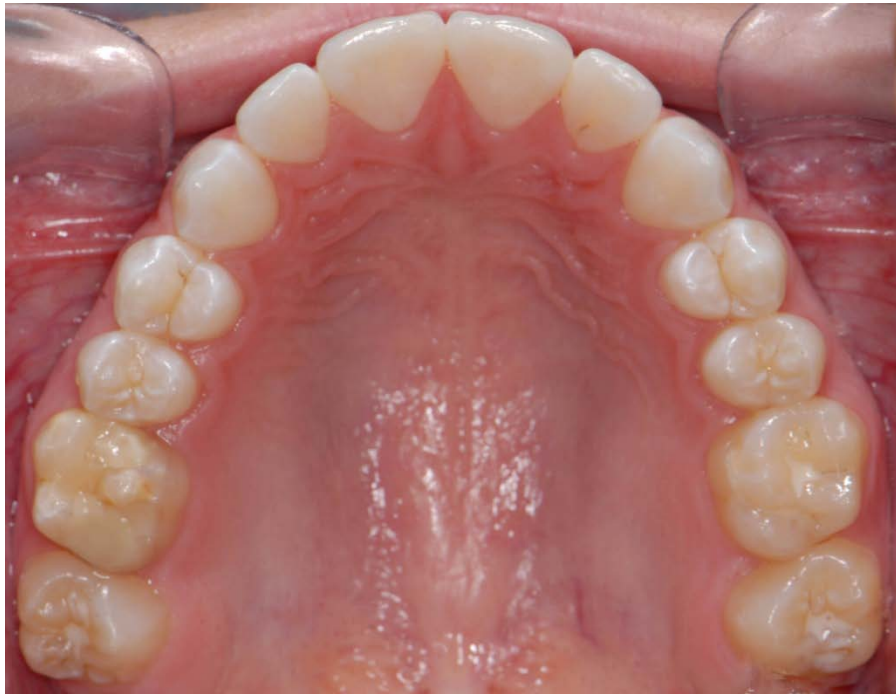- Occlusal plane should be horizontal and bisecting the photograph
- There should be equal display of the posterior dentition
- Teeth in occlusion



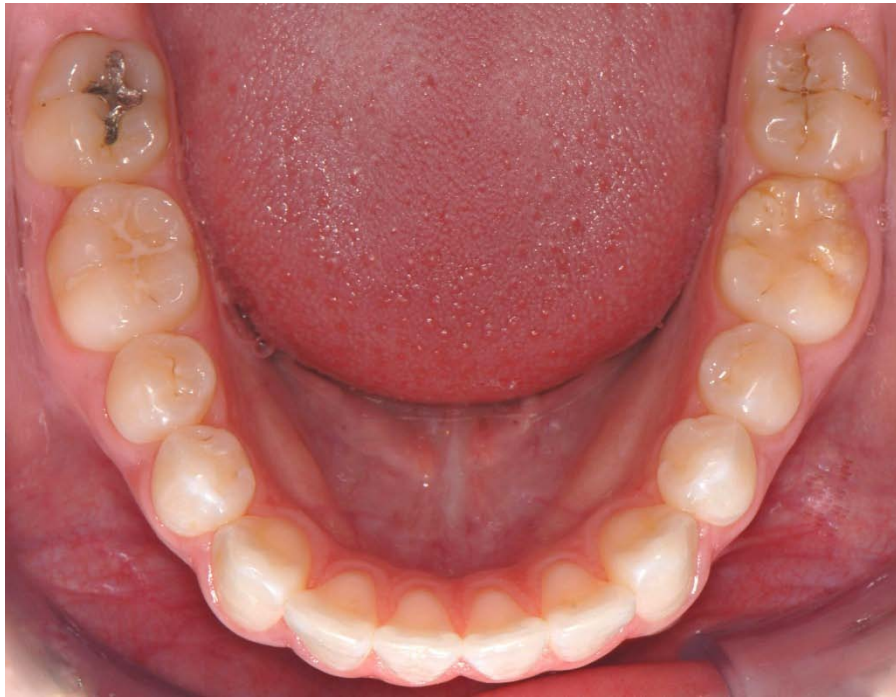- Anteriorly- should display the entire ipsilateral maxillary central incisor at minimum
- Posteriorly- include the entire first molars at minimum
- All attached gingiva should be visible
- Occlusal plane should be parallel to the frame



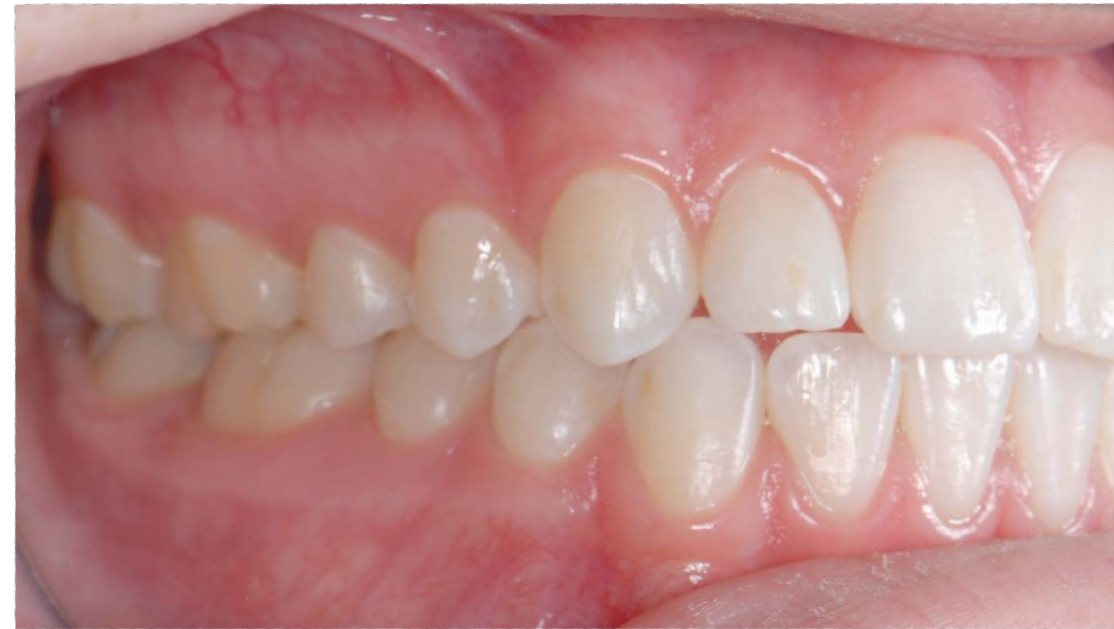- Use the same format as for the right lateral intraoral photograph



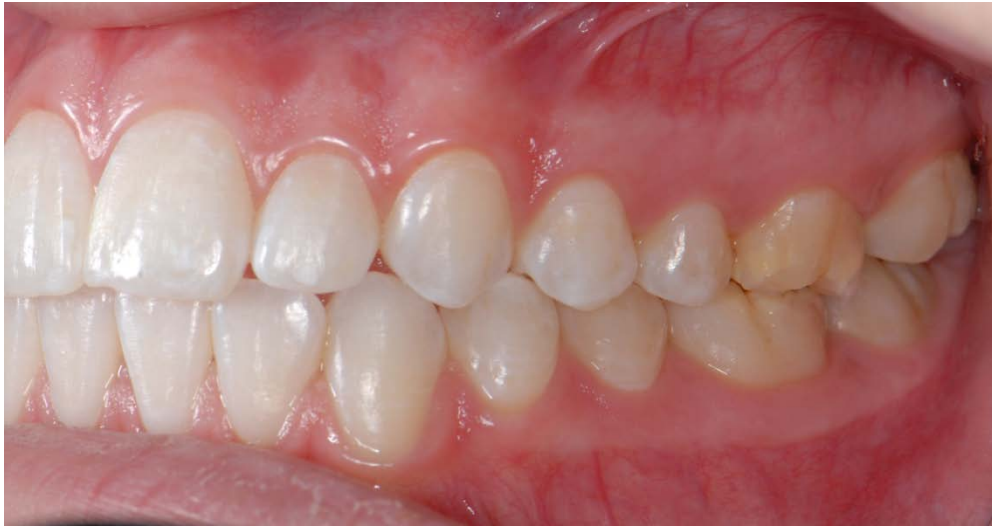- Mid-palatal raphe centered
- Frame the entire arch with minimal lateral soft tissue displayed



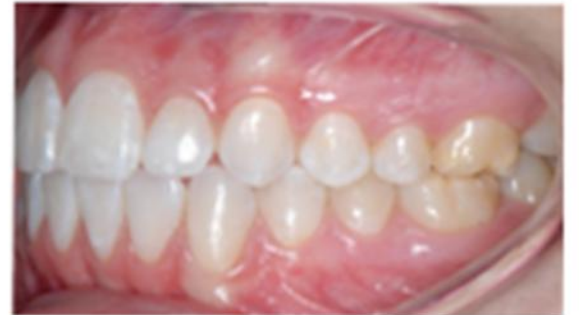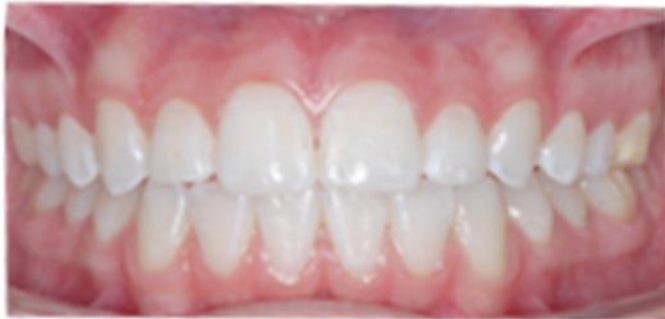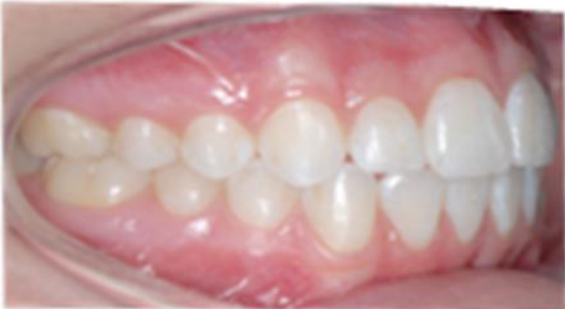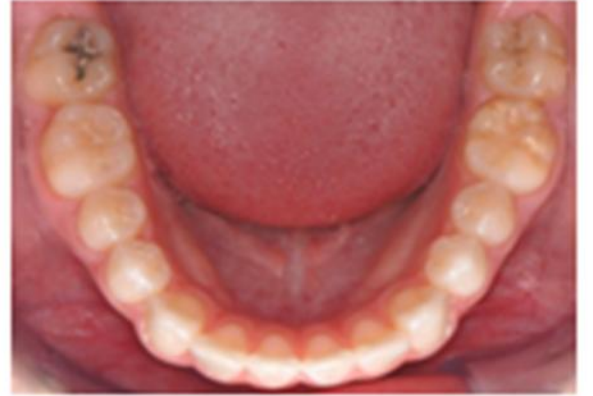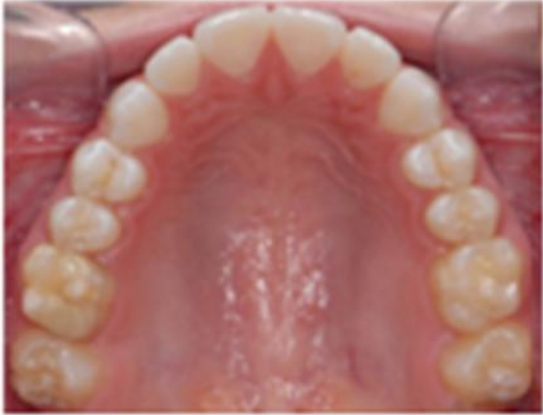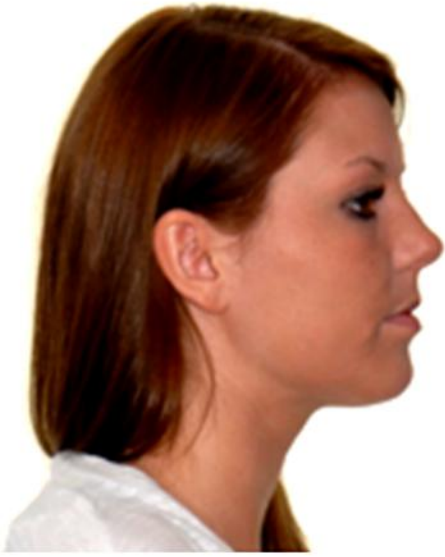- Fill the frame with the entire mandibular arch at least through the first molars
- Labial surface of the central incisors parallel to the bottom of the frame
- Midline centered in the frame



- Right mirror photograph flipped horizontally to appear as a direct photograph of the right side
- Extend view to second molars if possible

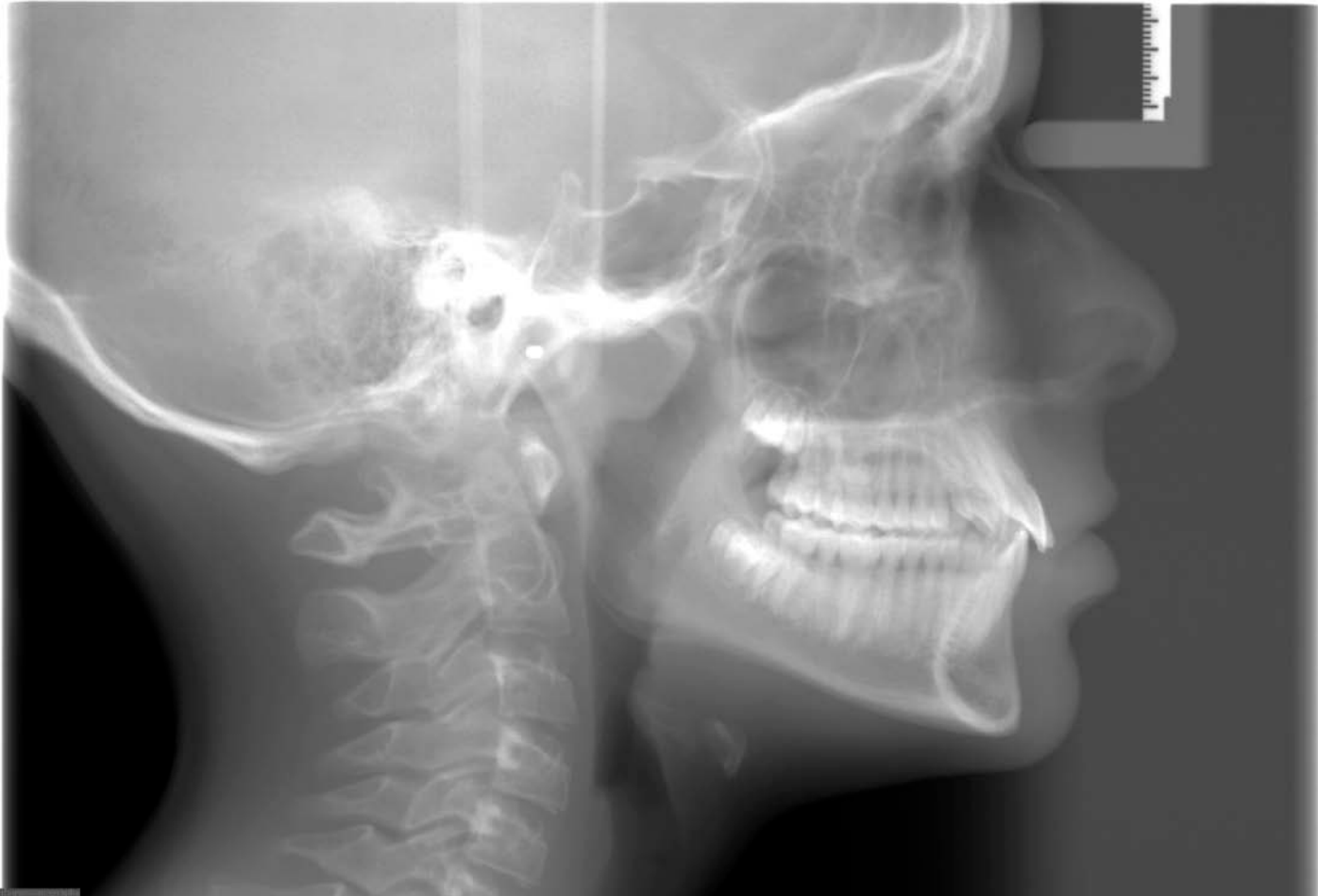

- Left mirror photograph: same requirements as right side occluded view



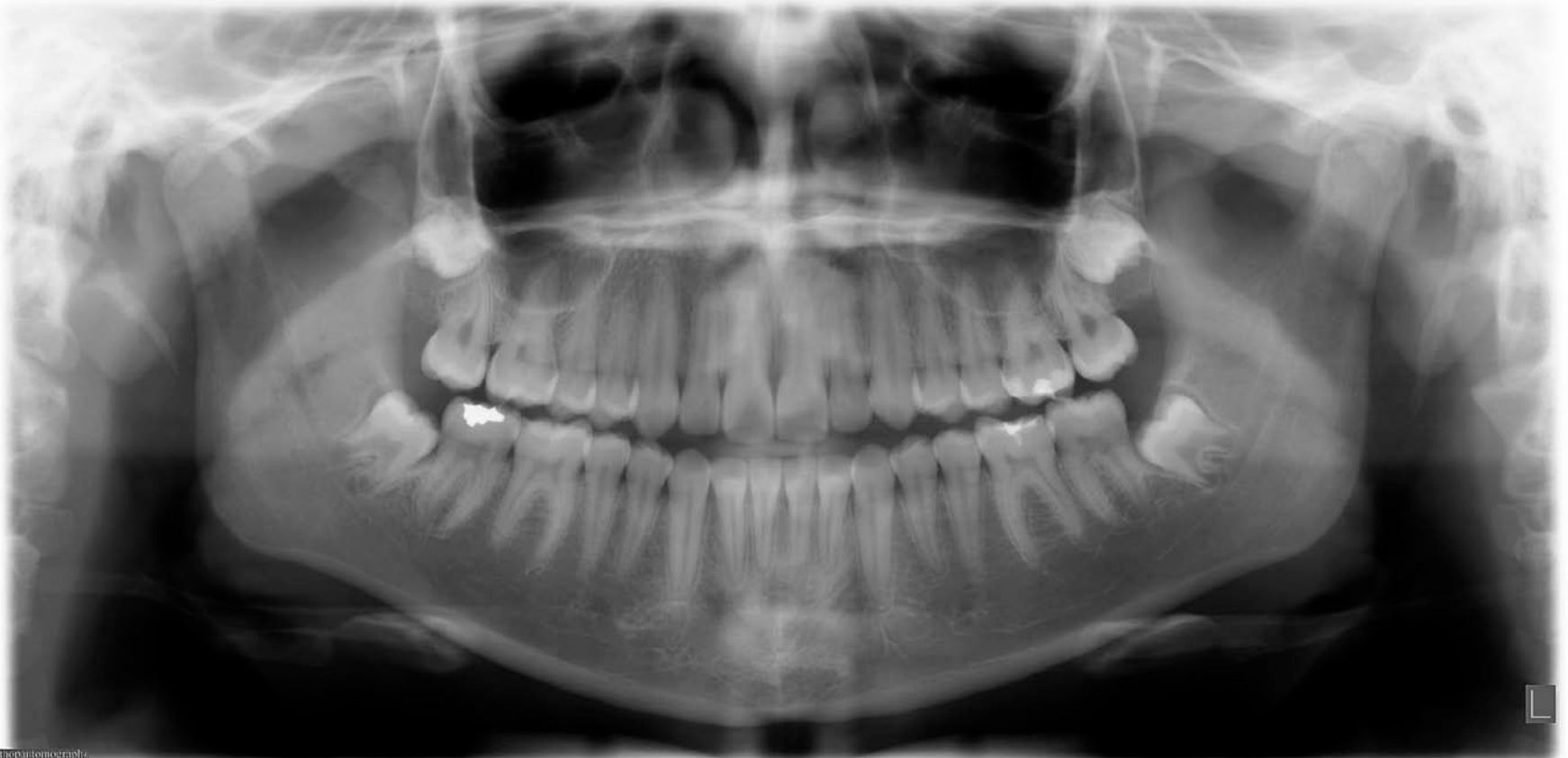Ideal Cephalometric Radiograph

- Full soft tissue is displayed
- Strongly recommend occipital region be visible
- Head is in natural position with Frankfort Horizontal plane parallel to the floor

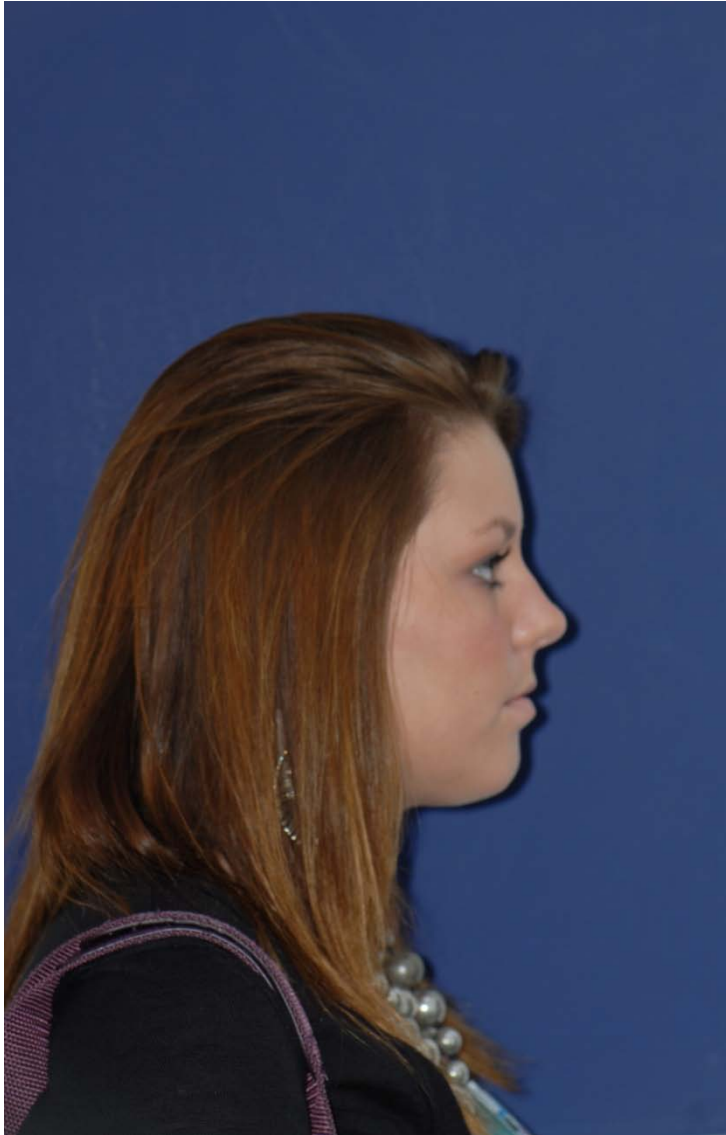

Ideal Panoramic Radiograph


- Patient orientation is correct
- Properly labeled (right & left)
- Correct exposure




Problem Photographs and Radiographs



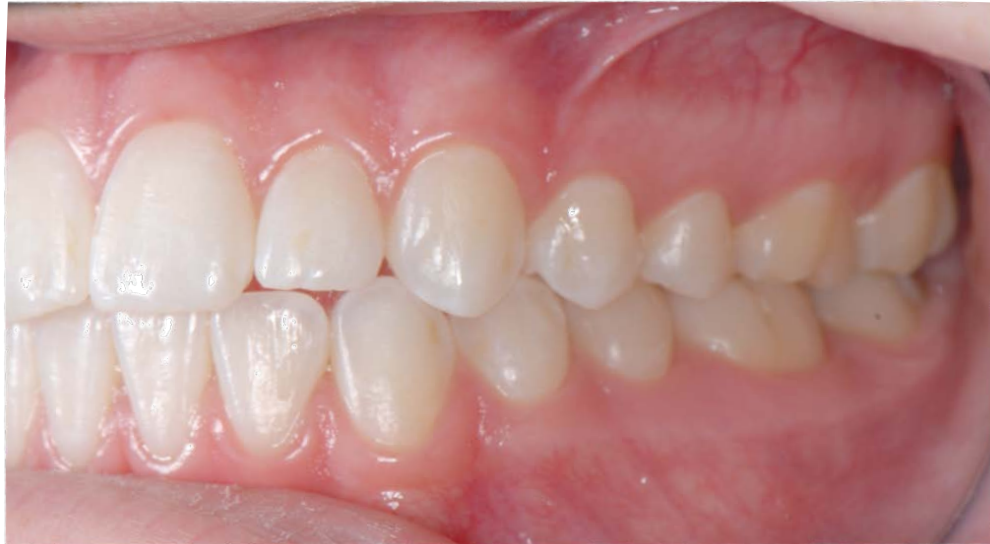- Poor diagnostic photograph with distractions and shadow creating double profile
- Prefer white background
- Patient too distant from the camera



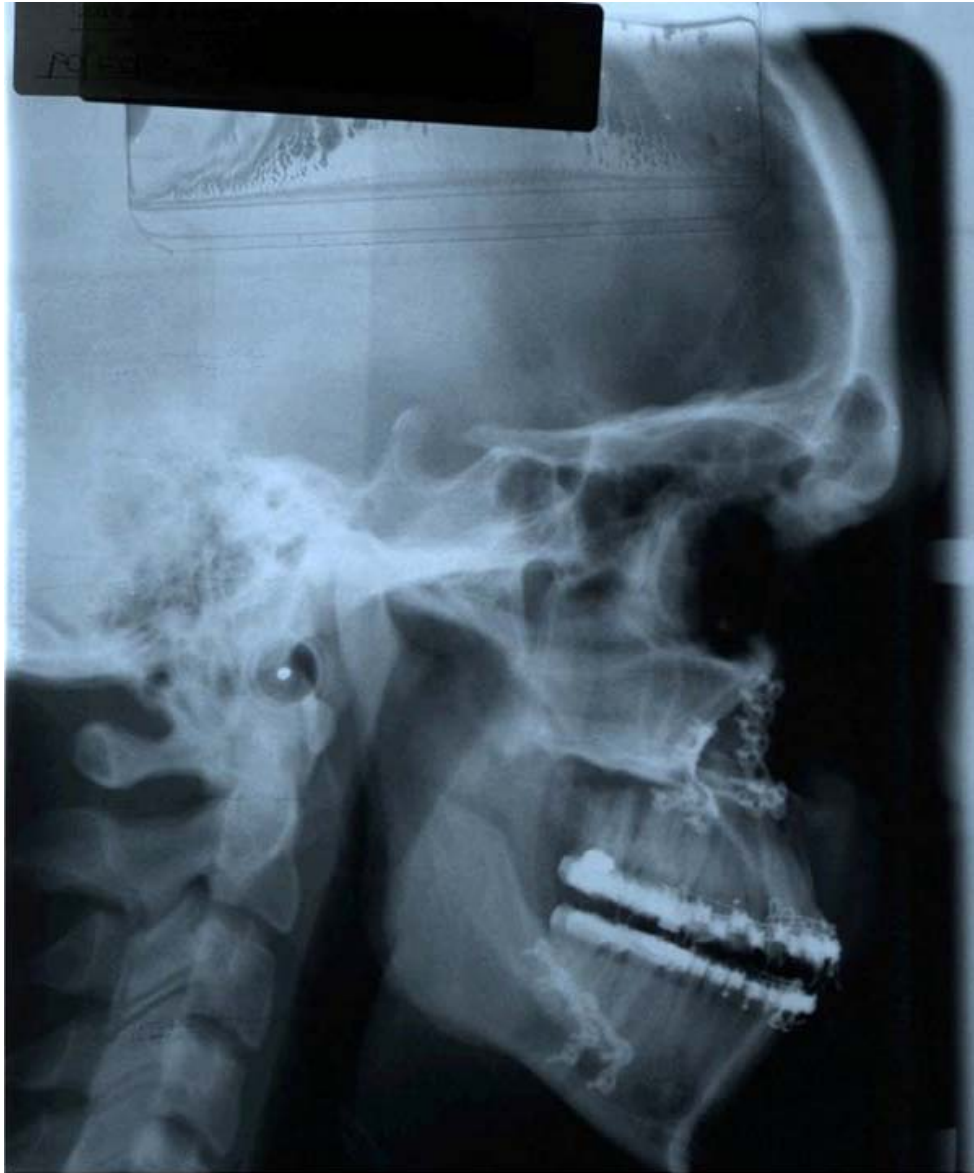- Head rotated and patient looking away from camera
- Distracting jewelry
- Hair covering ears with no visible landmarks
- Photograph should be cropped to display only face and neck area
- Photograph too dark



- Not a diagnostic profile view
- Distractions: jewelry and shadows present
- Improperly cropped
- Patient looking up and to the side

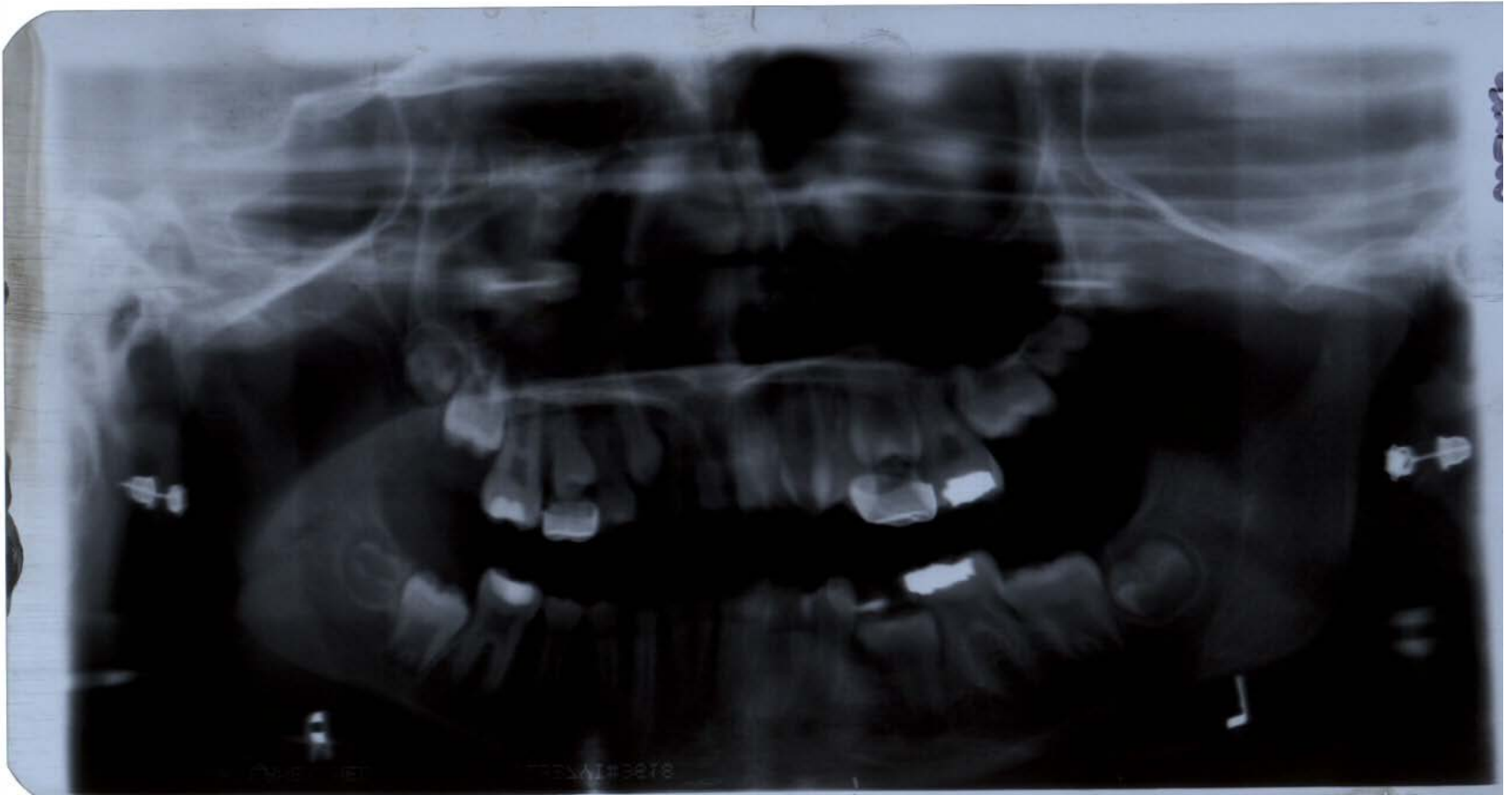

- Mirror image not corrected to represent patient's right side

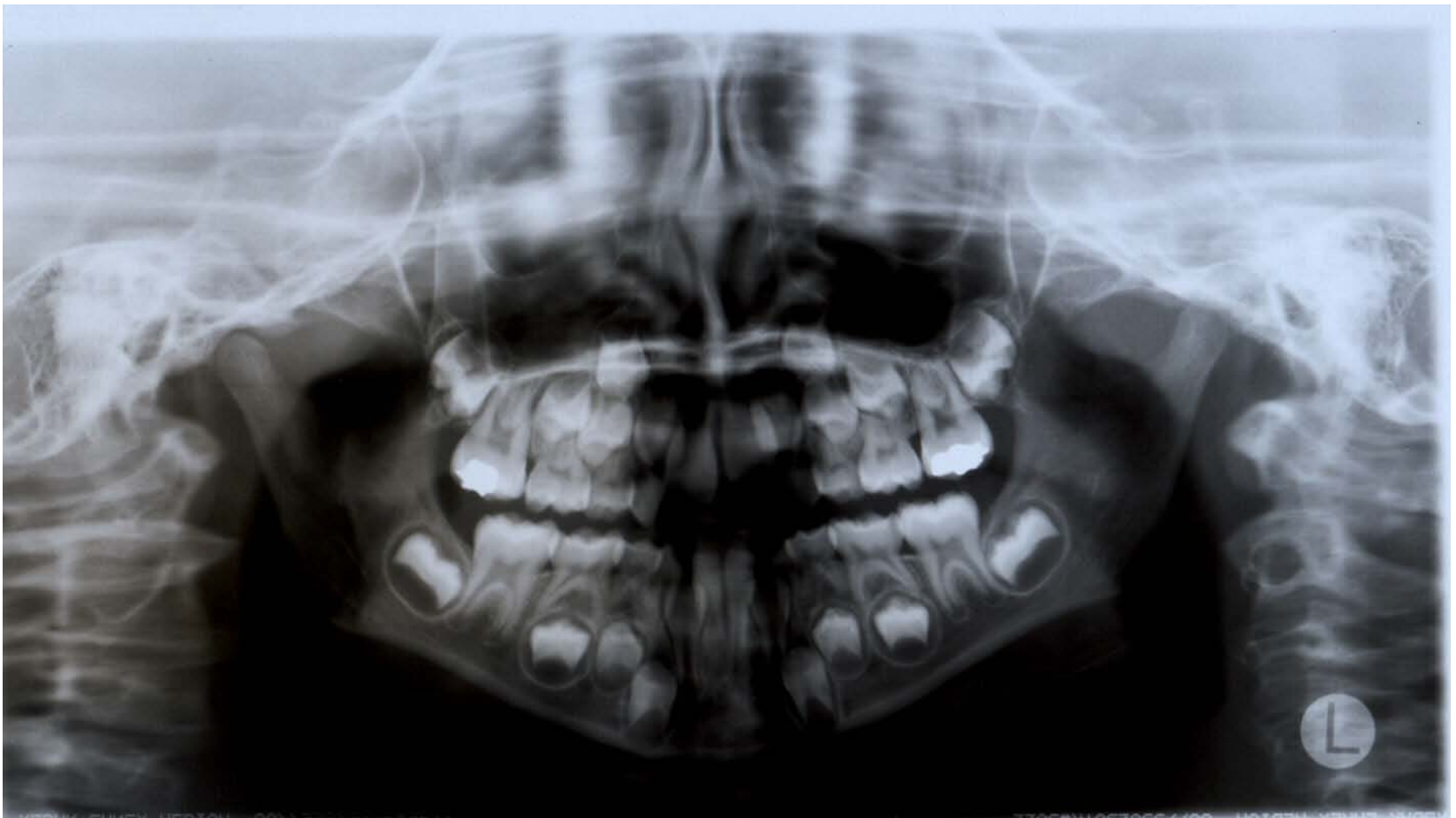

- Poor contrast
- Head is not in horizontal position
- Teeth are not in occlusion
- Soft tissue profile, occiput, and symphysis not visible

- Radiograph overexposed
- Symphysis not visible due to improper patient positioning
- Identification of right and left reversed
- Jewelry present



- Poor patient positioning causing distortion of the maxilla and mandible
- Excessive display of vertebral column



Poor patient positioning causing:

- Distortion of dental arches
- Condyles not visible
- Anterior teeth obscured

